

The specific case

Peri-implantitis treatment
with **CERASORB® M**

CERASORB®-Promise

CERASORB®.

Keeps its words in bone regeneration.

The specific case

+ Long Term Implantology

Peri-implantitis treatment with CERASORB® M

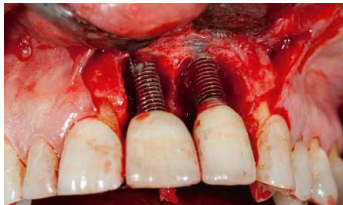“Peri-implantitis is the dental disease of the 21st century. The treatment should be regenerative, reproduce the missing bone tissue and reestablish good blood flow. For contemporary treatment and long-term success, I use CERASORB® M.”

Dr. Fernando Duarte, DDS, MSc
Clitrofa-Clinic / Trofa, Portugal

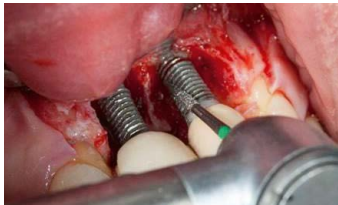+ Case History

A 59 years old patient visited the clinic presenting large bony defects surrounding two previously placed implants. Bleeding on probing was present, indicating an acute inflammation. However, no implant mobility could be observed. The x-ray scan supported the diagnosis of an advanced peri-implantitis [Fig. 1].

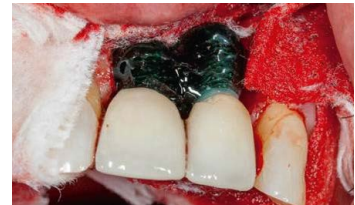[Fig. 2]



[Fig. 3]



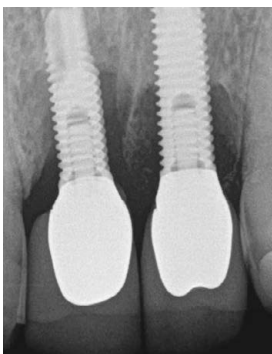
[Fig. 4]



A full mucoperiosteal flap with two vertical release incisions was first elevated. There was a massive defect around the implants [Fig. 2]. The physical debridement around the implants was first performed with diamond burs [Fig. 3]. Further treatment was conducted with a disinfectant solution containing Orthophosphoric acid and Chlorhexidine Digluconate.

Sodium Hyaluronate-Piperacillin-Tazobactam solution was then applied to provide a base for bone regeneration [Fig. 4].

T = Months

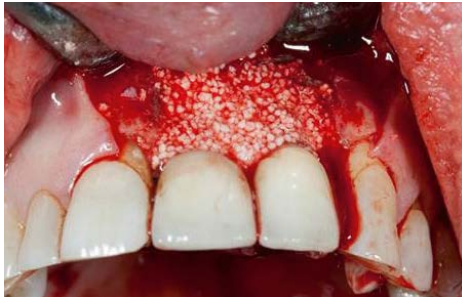

Pre-operative scan
[Fig. 1].

Take home messages

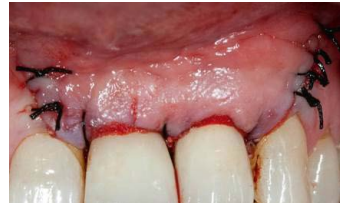- + **CERASORB® M** is one of the most hydrophilic materials for bone regeneration, which is a key factor for long-term success in peri-implantitis treatment.
- + Osseointegration of dental implants takes place in bone-tissue, not in bone material. Therefore bone regeneration materials such as **CERASORB® M** are the right treatment for this disease.
- + The quality of the regenerated bone tissue is the same as natural bone, and the results are always reproducible.

[Fig. 5]



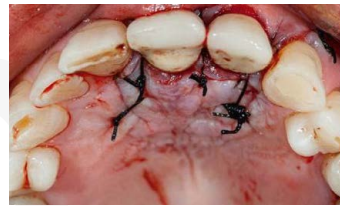CERASORB® M granules (500 – 1000 µm) were used to fill the defect and promote bone regeneration. The operation field was covered with Osgide®, a bioresorbable membrane for guided bone/tissue regeneration [Fig. 5].

[Fig. 6]



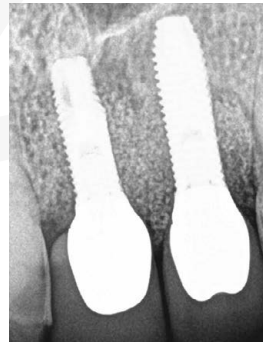
The margins of the defect were adapted by interrupted sutures [Fig. 6].

[Fig. 7]



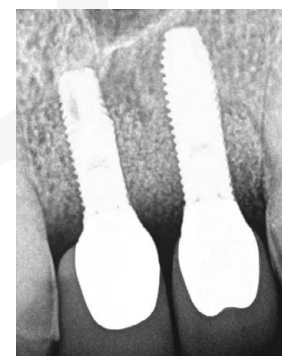Occlusal view of the defect after suturing [Fig. 7].

[Fig. 8]



Immediate post-op follow up [Fig. 8].

The 6 months post-op x-ray shows a sufficient bony regeneration in the former defect area [Fig. 9].



Post-operative scan [Fig. 9].

+ Proven Quality

CERASORB® M Granules

CERASORB® M are pure-phase, biomimetic β -TCP granules. Depending on the area of application, **CERASORB® M** granules are available in different grain sizes for oral surgery: 150 – 500 μm , 500 – 1.000 μm , and 1.000 – 2.000 μm .



Dental



Granules

Type of use:

- + Filling of defects after extirpation of bone cysts.
- + Augmentation of atrophied alveolar ridge, sinus lifting /sinus base elevation.
- + Peri-implantitis treatment.
- + Filling of defects after surgical removal of retained teeth.
- + In combination with autologous materials, cells and growth factors e.g. bone chips, BMA¹, PRP² or PRF³.

Handling:

- + **CERASORB® M** granules are soaked with patients' defect blood or bone marrow aspirate in a ratio of 1:1 or 1:2.

1 Bone Marrow Aspirate | 2 Platelet Rich Plasma | 3 Platelet Rich Fibrin

CERASORB® bone-regeneration materials.

We offer tailor-made solutions for diverse requirements.



You have our word!

curasan
Regenerative Medicine

curasan AG
Lindigstrasse 4
63801 Kleinostheim
Germany
cerasorb@curasan.de
www.curasan.de



CERASORB® – Always First Choice.